

# Overwhelming Paroxysmal Nocturnal Haemoglobinuria in a Patient with Low-Risk Myelodysplastic Syndrome and Long-Term Anticoagulation for Sick Sinus Syndrome

Vincent Éthier<sup>1</sup>, Marie-Claude Foley<sup>1</sup>, Sarah Higgins<sup>2</sup>, Régen Drouin<sup>3</sup>, Julie Abel<sup>4</sup>, Rabia Temmar<sup>5</sup>, Rami Kotb<sup>1</sup> and Hans Knecht<sup>1,\*</sup>

<sup>1</sup>Division d'Hématologie, Département de Médecine, CHUS, Université de Sherbrooke, Québec, Canada

<sup>2</sup>Division de Néphrologie, Département de Médecine, CHUS, Université de Sherbrooke, Québec, Canada

<sup>3</sup>Service de Génétique, Département de Pédiatrie, Faculté de Médecine et des Sciences de la Santé, Université de Sherbrooke, Québec, Canada

<sup>4</sup>Soins Intensifs, Département de Médecine, CHUS, Université de Sherbrooke, Québec, Canada

<sup>5</sup>Département de Pathologie, CHUS, Université de Sherbrooke, Québec, Canada

**Abstract:** Paroxysmal nocturnal haemoglobinuria (PNH) is a rare form of acquired Coombs negative haemolytic anaemia manifested by the clinical triad of intravascular haemolysis, venous thrombosis and cytopenia. At the molecular level PNH is defined by a clonal expansion of hematopoietic stem cells having undergone somatic mutation of the X-chromosome gene *PIG-A*. Here we report the case of an 80-year old female patient known for sick sinus syndrome for more than 30 years and low-risk myelodysplastic syndrome (MDS) with uneventful course over the past two years. In good health she underwent her fifth lead replacement under short-term reversal of anticoagulation. Two weeks later she presented at the emergency room for epigastric pain, vomiting and fever. Work up revealed extensive right jugular vein thrombosis, Coombs-negative haemolytic anaemia and acute renal failure. Paroxysmal nocturnal haemoglobinuria was suspected and confirmed by flow cytometric FLAER-assay, which detects clonal deficiency of glycosyl-phosphatidylinositol linked surface proteins on monocytes and granulocytes. Thus, search of a PNH clone with FLAER was reliable in the presence of RBC-transfusions and ongoing intravascular haemolysis. Though stabilization of haemolysis was achieved, renal failure progressed and the patient deceased suddenly at the 11<sup>th</sup> day of hospitalization. Short-term reversal of anticoagulation and functionless retained pacing leads may have catalyzed thrombosis in our MDS patient with a large glycosyl-phosphatidylinositol (GPI) deficient clone. In MDS patients under long-term anticoagulation any short-term reversal of anticoagulation for surgical procedures should be preceded by FLAER analysis to uncover an emerging GPI-deficient clone since recent developments in the treatment of this condition allow prevention of intravascular haemolysis and thrombosis by halting the complement cascade at the C5 level with targeted immunotherapy.

**Keywords:** Low-risk MDS, PNH, long-term anticoagulation, vomiting, Sick-sinus syndrome, pacemaker, lead replacement.

## INTRODUCTION

Increased sensitivity of red blood cells to complement-mediated attack is responsible for most clinical manifestations of PNH, which include haemolytic anaemia, venous thrombosis and cytopenia, mainly thrombocytopenia [reviewed in 1]. PNH is defined by a clonal expansion of hematopoietic stem cells that have undergone somatic mutation of the X-chromosome gene *PIG-A*. The product of this gene is essential for synthesis of glycosyl-phosphatidylinositol (GPI), which acts as an anchor to the membrane for many surface proteins of blood cells [reviewed in 2]. *PIG-A* mutated cells therefore lack expression of different surface proteins. Blood cells of PNH patients have reduced expression CD55 and

CD59, two proteins implicated in complement inhibition [1-3]. The size of the PNH clone usually correlates with the degree of symptoms. Most patients have chronic low-grade haemolysis that can be exacerbated by infection, surgery, stress, or anything else that initiates complement activation. Episodes of severe intravascular haemolysis do occur. In these cases, released free haemoglobin overwhelms haptoglobin binding capacity and leads to haemoglobinuria. Once in circulation, free haemoglobin irreversibly binds nitric oxide molecules. Depletion of NO in patients with PNH leads to smooth muscle dystonia, which may be responsible for many of the symptoms of the disease including esophageal spasm, dysphagia and abdominal pain [2, 4]. Moreover, NO depletion induces vessel constriction and triggers platelet activation and aggregation, resulting in thrombus generation [4]. In this report we describe a patient diagnosed with low-risk MDS who presented at the emergency room (ER) for epigastric pain and vomiting.

\*Address corresponding to this author at the Division of Haematology/Oncology, CHUS University Hospital, 3001 12<sup>th</sup> Avenue North, Sherbrooke (Québec), Canada; Tel: ++1 819 346 1110 ext 14816; Fax: ++1 819 564 5434; E-mail: hans.knecht@usherbrooke.ca

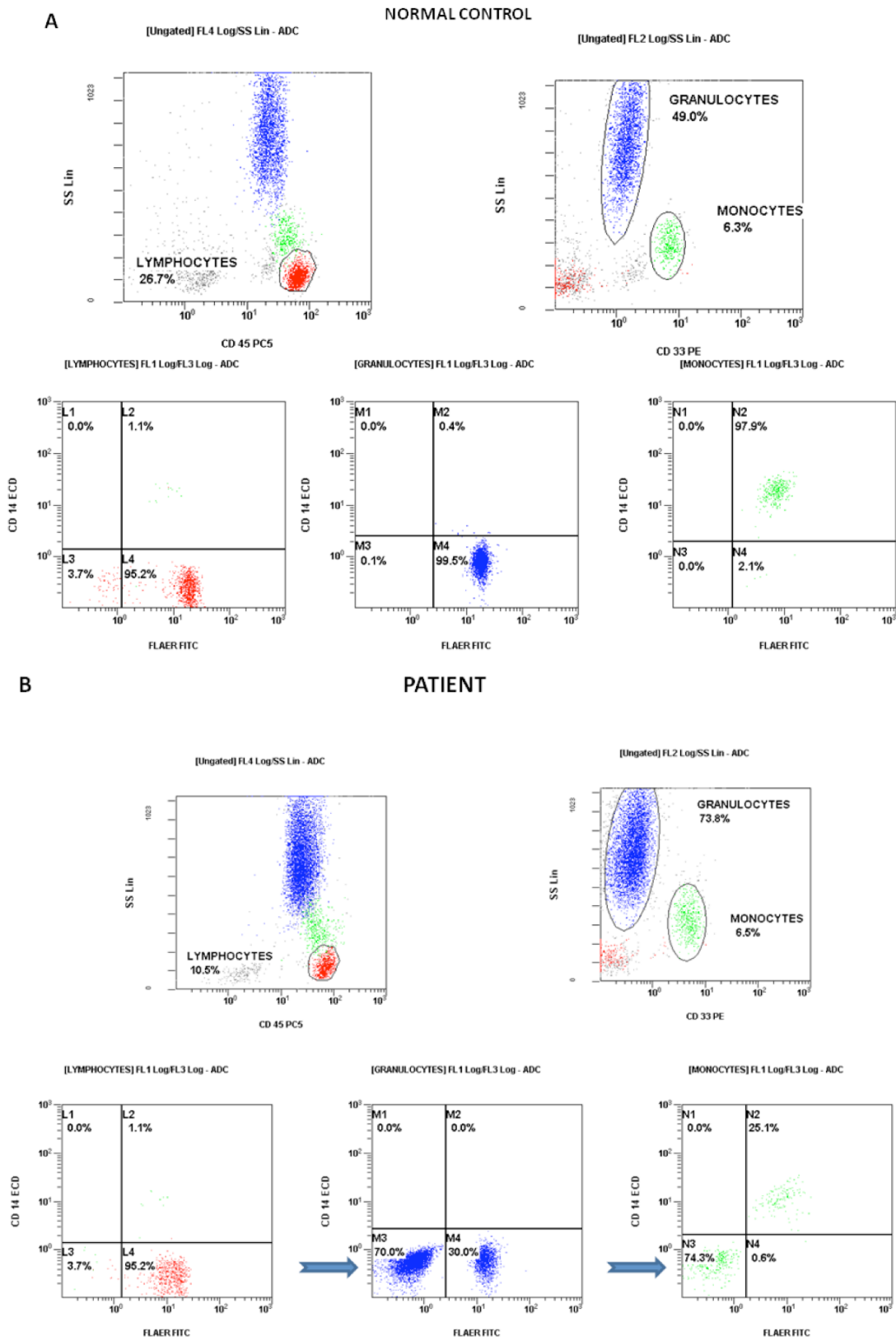
## CASE PRESENTATION

An 80 years old woman presented to the ER for acute epigastric pain of unknown aetiology accompanied by vomiting and fever. She also mentioned right shoulder pain present for a few days and increasing by arm movement. She was known for a sick sinus syndrome treated with a permanent pacemaker since 1975, for which she underwent a new (the fifth) lead replacement under short-term anticoagulation reversal (INR of 1.1) in the right subclavian vein two weeks prior to her presentation to the ER. Notably, phlebography of the right superior member, performed at the day of lead replacement, mentioned opacification of the subclavian vein. She was also followed by her haematologist for a low-risk MDS diagnosed two years before by bone marrow aspiration, bone marrow cytogenetics and bone marrow histology. Bone marrow was moderately hypocellular (15%) with signs of dysmegakaryopoiesis but without myelofibrosis. Cytogenetic analysis revealed an interstitial deletion of the long arm of chromosome 20 (46, XX, del(20)(q11.2q13.1) in 25% of the metaphases and around 11,5% of the bone marrow cells. Over a two year's regular follow-up CBC and anticoagulation were stable (haemoglobin of 102-112 g/L; reticulocytes 26-54 G/L; mean globular volume 96-104 fl; neutrophils of 1.1-2.0 G/L; platelets of 80-130 G/L; INR of 2.1-3.0; D-dimers < 400 mcg/L). LDH was slightly elevated (267-462 UI/L; upper normal range 235 UI/L) but total bilirubine was still normal between 7.2 and 13.2  $\mu\text{mol/L}$ . Serum erythropoietin was significantly elevated with 32.6 mU/ml (normal range 2-19). Since the MDS was of low risk and regular CBC controls at a 6-8 week interval (16 controls over two years) showed stable haemoglobin and platelet counts neither initial nor follow-up testing for a PNH clone was performed. The patient felt to be in good health, had no RBC transfusion requirements and no infectious or thrombotic events were reported.

Routine blood tests ordered by her cardiologist two days before presentation to ER showed a haemoglobin of 100 g/L, neutrophils of 3.2 G/L, platelets of 165 G/L and INR of 2.0. On ER presentation, CBC showed haemoglobin of 74 g/L, reticulocyte count of 36 G/L, neutrophils of 3.7 G/L, platelets of 140 G/L and fever of 38.8°C. C-reactive protein was elevated at 276.4 mg/L (normal <8 mg/L). She noticed red coloured urine prior to admission but no bloody stool or any other bleeding event. Blood tests were consistent with intravascular haemolytic anaemia (LDH 1987, haptoglobin <0.3 g/L, total bilirubin 29.9  $\mu\text{mol/L}$ , free

plasmatic haemoglobin 0.5 g/L). Direct Coombs test was negative and peripheral blood smear showed some dacryocytes, very few schizocytes and spherocytes but no immature myeloid cells (blasts). Coagulation system analysis revealed INR of 4.5, aPTT of 49,9 seconds (range 23-32 seconds), fibrinogen of 7.9 g/L (range 1.8-4.5 g/L), D-dimers of 1671 mcg/L (normal < 500 mcg/L) consistent with ongoing factor consumption, fibrinolysis and inflammation. Biochemistry also showed acute renal failure with creatinine at 306  $\mu\text{mol/L}$  and BUN at 22.8 mmol/L.

The patient was started on empirical antibiotherapy (vancomycin and piperacillin/tazobactam) and admitted to the ICU. Urine culture showed significant *Escherichia coli* growth. Urine color at admission was dark yellow but cleared up after two days. Venous Doppler ordered for her right shoulder pain revealed extensive right jugular vein thrombosis and intravenous heparin was started. Other imaging investigations were negative for occult infection or blood collections. In particular, on abdominal CT-scan performed the morning after admission the kidneys and both ureters appeared normal. A 2D/Doppler echocardiogram, performed at the fourth day of hospitalization, showed a conserved left ventricular function and no signs of atrial thrombosis. Haemoglobin levels further dropped to 65 g/L needing transfusion of two units of packed RBC within the first day after admission. Determination of coagulation factors confirmed decreased activity of vitamin-K dependent factors (factor II at 22%, factor VII at 17%, factor IX at 33% and factor X at 21%), normal activity of factors XI and XII, but increased activity of factor V (161%) and factor VIII (> 300%). In presence of intravascular haemolysis and extended thrombosis PNH was suspected. Flow cytometric FLAER-assay, which detects clonal deficiency of glycosyl-phosphatidyl-inositol linked surface proteins on monocytes and granulocytes [5], identified a dominant FLAER negative clone of about 70% in both populations (Figure 1) corroborating the clinical diagnosis of PNH. Still ongoing haemolysis required transfusion of a third unit of packed RBCs but then stabilized with a haemoglobin level of about 80 g/L and haemolysis parameters returning to normal (haptoglobin 0.55 g/L, total bilirubin 9.0  $\mu\text{mol/L}$ , free plasmatic haemoglobin 0.03 g/L) apart a still moderately elevated LDH at 682 UI/L. Body temperature (rectal) lowered to 37.0-37.6°C. Platelet count remained stable ranging between 100 and 132 G/L and D-dimers lowered to 1177 mcg/L, but acute renal failure persisted with creatinine at 427



**Figure 1: Flow Cytometry Diagnosis of PNH with FLAER.**

**A.** Normal peripheral blood control shows lymphocytes (red, CD14-, FLAER+), granulocytes (blue, CD14-, FLAER+), and monocytes (green, CD14+, FLAER+). Less than 0.5% of granulocytes and monocytes show a FLAER negative PNH phenotype.

**B.** Patient's peripheral blood (after red blood cell transfusion) reveals an overwhelming PNH clone (bold arrows) of more  $\geq 70\%$  of granulocytes (CD14-, FLAER-) and monocytes (CD14-, FLAER-) affected. Lymphocytes with a very long lifespan were generated before onset of the PNH clone and are therefore not affected.

µmol/L and BUN at 18.0 mmol/L. A second abdominal CT-scan performed at day 8 of hospitalization again showed the kidneys and both ureters appearing normal. However, at abdominal echography done the same day the left renal vein could not be visualized, the other intra-abdominal veins showing no abnormality. Intravenous vancomycin was stopped at day 9 but piperacillin/ tazobactam continued. A second morphological analysis of peripheral blood smear at the 10<sup>th</sup> day of hospitalization showed no signs of mechanical haemolysis (only slight anisocytosis and slight poikilocytosis without schizocytes), absence of immature myeloid cells (blasts) but surprisingly neutrophil leucocytosis at 8.3 G/L and presence of toxic granulations within the neutrophil granulocytes. In presence of a still moderately elevated LDH, rising D-dimers (2219 mcg/L) and the possibility of left renal vein thrombosis treatment with the monoclonal antibody eculizumab was considered to prevent recrudescence of intravascular haemolysis and thrombosis. However, renal failure rapidly deteriorated (creatinine from 395 to 588 µmol/L within 48 hours) requiring haemodialysis. Cardiac arrest surprisingly occurred during haemodialysis catheter placement at the 11<sup>th</sup> day of hospitalization. Post mortem was not performed.

## DISCUSSION

PNH should be suspected whenever Coombs-negative intravascular haemolytic anaemia is present. It is nonetheless a rare disease, with recent estimates giving an incidence up to 5 cases per million of births [6]. Diagnosis is made using flow cytometry; one criterion is the absence of at least 2 GPI-linked structures (usually CD55 and CD59) detected on more than one cell lineage, typically neutrophils in addition to erythrocytes and reticulocytes [5, 7]. However, cytometric analysis of red blood cells can be affected by recent RBC transfusions and ongoing haemolysis. Most recent techniques make use of the FLAER reagent, as in our case [5]. It consists of a fluorochrome-labeled inactive variant of the protein proaerolysin, whose active form selectively binds to the GPI anchor. Proaerolysin is a toxin produced by *Aeromonas hydrophila* to form channels on target cells resulting in their lysis after having been processed to its active form aerolysin. The non-lysing mutated form of proaerolysin (FLAER) can therefore be used to estimate the PNH clone size on monocytes and neutrophils. It has been shown that FLAER combined with multiparameter flow cytometry can accurately detect PNH clones with improved sensitivity without

being influenced by recent RBC transfusions [8]. However, significant abnormalities in CD55 and CD59 expression restricted to neutrophils and the myeloid lineage rarely do occur in autoimmune disorders [9] or during transformation of MDS into acute leukemia and could be a sign for circulating immature myeloid cells or pre-analytic problems with an increased rate of apoptotic cells. (Britta Höchsmann, personal communication). In our patient there were no signs of transformation of MDS into acute leukemia since haemoglobin dropped from 100g/L to 74 g/L within only 48 hours while neutrophils and platelets were still in normal range and circulating blasts were not observed. Moreover, during the haemolytic crisis the neutrophil count had doubled compared to the average count identified since diagnosis of MDS, and neutrophil count raised even to 8.3 G/L the day before death thus indicating a still functional stress reserve of the bone marrow. This, together with the identification of toxic granules within these neutrophils is consistent with an underlying infection or a stress reaction to extended thrombosis. There were also neither signs and symptoms nor anamnestic data to suspect the setting of an autoimmune disorder.

GPI anchor protein-deficient cells have been detected in some cases of myelodysplastic syndrome, especially when associated with a hypocellular marrow [2] as in our patient, where bone marrow aspiration and bone marrow biopsy were diagnostic of MDS using standard criteria and where cytogenetics showed an interstitial deletion of the long arm of chromosome 20. This deletion is usually classified in the good-prognosis MDS category with a median overall survival > 5 years [10]. CBCs were stable during 2 years without any transfusion needs. We explained the elevated serum erythropoietin level associated with a reticulocyte count at the lower limit of the normal range in presence of slightly elevated LDH but normal D-dimer levels with inefficient erythropoiesis in the context of MDS and found no need to test initially for the presence of a PNH clone. On the other hand, the repeatedly elevated LDH is consistent with the hypothesis of a PNH clone already present at diagnosis of MDS [1] and expanding during follow-up but that ongoing long-term anticoagulation for sick sinus syndrome avoided thrombosis to occur. We hypothesize that anticoagulation reversal for the pacemaker lead replacement favoured thrombosis. It occurred in the right jugular vein, near a site where thrombosis predisposition might have been already present [11] because of the multiple functionless pacemaker leads

that were left in place in the subclavian vein after replacement (the patient had 5 such replacements). The opacification the right subclavian vein, identified by phlebography at the day of lead replacement sustains this hypothesis. It appears quite possible that thrombus formation was initiated by the lead capping and pacemaker exchange associated with endothelial irritation leading to platelet activation which in the context of short time reversal of anticoagulation led to extensive thrombosis. There are also several hints that renal failure was PNH related and not due to another disorder, in particular HUS (haemolytic uremic syndrome): At hospitalization day 8 the left renal vein could not be visualized, impaired renal function persisted, and terminally progressed in spite of normalization of haemolysis parameters, stable platelet count and absence of schizocytes in the peripheral blood smear. Contrary to the haemolysis parameters D-dimers increased preterminally, consistent with recrudescence of thrombosis/fibrinolysis. In this situation we considered to start treatment with eculizumab who has been successful in an analogous context of repeated life-threatening thrombotic complications [12]. Unfortunately, the patient died from cardiac arrest during haemodialysis catheter placement. Thrombosis at an additional site, i.e. coronary artery occlusion [12], central nervous system thrombosis, or pulmonary embolism, might well be responsible for the patient's sudden death [1]. However, formal proof that renal failure and cardiac arrest were PNH related is missing since post mortem was not performed.

In low-risk MDS patients under long-term anticoagulation major PNH clones may emerge without signs and symptoms except a slight increase of LDH as a sign of subclinical haemolysis [1]. In such patients minor surgical procedures associated with small vascular endothelial damage, as in the case of pacing lead replacement and functionless retained pacing leads, may catalyze thrombosis. Short-term reversal of anticoagulation appears to be an additional trigger of fatal thrombosis. Therefore, screening for emerging PNH clones at 6 months' intervals [2, 3] and prior to invasive interventions appears to be mandatory even in patients with low-risk MDS.

## CONSENT

Written informed consent was obtained from the patients' family for publication of this case report. The original of the written consent is available to the Editor-in-Chief of this journal.

## COMPETING INTERESTS

The authors have no competing interests to declare.

## AUTHORS' CONTRIBUTIONS

VE and M-CF reviewed the literature and prepared the manuscript; SH was the nephrologist involved in patient management; RG and RT established diagnosis of MDS; JA managed patient care at the ICU; RK and HK established the diagnosis of PNH. HK was her treating haematologist and finalized the manuscript. All authors have read and approved the final manuscript.

## REFERENCES

- [1] Luzzatto L, Gianfaldoni G, Notaro R. Management of paroxysmal nocturnal haemoglobinuria: a personal view. *Brit J Haematol* 2011; 153: 709-20. <http://dx.doi.org/10.1111/j.1365-2141.2011.08690.x>
- [2] Parker C, Omine M, Richards S, Nishimura J, Bessler M, Ware R, *et al.* Diagnosis and management of paroxysmal nocturnal hemoglobinuria. *Blood* 2005; 106: 3699-709. <http://dx.doi.org/10.1182/blood-2005-04-1717>
- [3] Borowitz MJ, Craig FE, Digiuseppe JA, Illingworth AJ, Rosse W, Sutherland DR, *et al.* Guidelines for the diagnosis and monitoring of paroxysmal nocturnal hemoglobinuria and related disorders by flow cytometry. *Cytometry B Clin Cytom* 2010; 78: 211-30.
- [4] Rother RP, Bell L, Hillmen P, Gladwin MT. The clinical sequelae of intravascular hemolysis and extracellular plasma hemoglobin: a novel mechanism of human disease. *JAMA* 2005; 293: 1653-62. <http://dx.doi.org/10.1001/jama.293.13.1653>
- [5] Sutherland DR, Kuek N, Davidson J, Barth D, Chang H, Yeo E, *et al.* Diagnosing PNH with FLAER and multiparameter flow cytometry. *Cytometry B Clin Cytom* 2007; 72: 167-77. <http://dx.doi.org/10.1002/cyto.b.20151>
- [6] Gulbis B, Eleftheriou A, Angastiniotis M, Ball S, Surrallés J, Castella M, *et al.* Epidemiology of rare anaemias in Europe. *Adv Exp Med Biol* 2010; 686: 375-96. [http://dx.doi.org/10.1007/978-90-481-9485-8\\_22](http://dx.doi.org/10.1007/978-90-481-9485-8_22)
- [7] Höchsmann B, Rojewski M, Schrezenmeier H. Paroxysmal nocturnal hemoglobinuria (PNH): higher sensitivity and validity in diagnosis and serial monitoring by flow cytometric analysis of reticulocytes. *Ann Hematol* 2011; 90: 887-99. <http://dx.doi.org/10.1007/s00277-011-1177-4>
- [8] Sutherland DR, Kuek N, Azcona-Olivera J, Anderson T, Acton E, Barth D, *et al.* Use of a FLAER-based WBC assay in the primary screening of PNH clones. *Am J Clin Pathol* 2009; 132: 564-72. <http://dx.doi.org/10.1309/AJCPMRDZZFQM7YJ4>
- [9] Ruiz-Delgado GJ, Vázquez-Garza E, Méndez-Ramírez N, Gómez-Almaguer D. Abnormalities in the expression of CD55 and CD59 surface molecules on peripheral blood cells are not specific to paroxysmal nocturnal hemoglobinuria. *Hematology* 2009; 14: 33-7. <http://dx.doi.org/10.1179/102453309X385089>
- [10] Mullier F, Daliphard S, Garand R, Dekeyser M, Cornet Y, Luquet I, *et al.* Morphology, cytogenetics, and survival in myelodysplasia with del(20q) or ider(20q): a multicenter study. *Ann Hematol* 2012; 91: 203-13. <http://dx.doi.org/10.1007/s00277-011-1286-0>
- [11] Zerbe F, Ponizynski A, Dyszkiewicz W, Ziemiański A, Dziegielewski T, Krug H. Functionless retained pacing leads

in the cardiovascular system. A complication of pacemaker treatment. *Brit Heart J* 1985; 54: 76-9.  
<http://dx.doi.org/10.1136/hrt.54.1.76>

[12]

Schutgens RE, Pruissen-Peeters KA, Muus P. A cascade of thromboembolic processes in a patient with paroxysmal nocturnal haemoglobinuria terminated by treatment with eculizumab. *Thromb Haemost* 2011; 106: 383-85.  
<http://dx.doi.org/10.1160/TH11-03-0165>

---

Received on 03-10-2012

Accepted on 28-11-2012

Published on 31-01-2013

<http://dx.doi.org/10.6000/1927-7229.2013.02.01.7>

© 2013 Éthier *et al.*; Licensee Lifescience Global.

This is an open access article licensed under the terms of the Creative Commons Attribution Non-Commercial License (<http://creativecommons.org/licenses/by-nc/3.0/>) which permits unrestricted, non-commercial use, distribution and reproduction in any medium, provided the work is properly cited.