

Osteosarcoma of Cervical Spine: Report of a Case Treated with Hadrontherapy

Leonello Tacconi^{1,*}, Gennaro D'acunzi², Raffaele Fristachi³ and Filippo Aquila¹

¹Neurosurgical Unit, Azienda Universitaria Integrata, Trieste, Italy

²Neurosurgical Unit, ASL Salerno, Italy

³UOC Anatomia Patologica, ASL Salerno, Italy

Abstract: Sarcomas are rare tumours that commonly derive from neoplastic transformation of mesenchymal tissues. Only a small percentage of these malignancies are located in the spine. The gold standard of treatment is a multidisciplinary approach with the surgery being the most important tool. An en-bloc resection with free margins followed by radiotherapy seems to assure the best overall survival. Among the newest treatment modalities, certainly, the adrontherapy is the most interesting and promising kind of radiotherapy that uses the physical bullet properties (Bragg peak) of protons such as carbon ions to treat lesions. We present a case of a gentleman with a C2-C3 low grade osteosarcoma treated, after a biopsy tissue sample, with hadrontherapy alone. At 6 years follow up the tumour seems to be well under control.

Keywords: Osteosarcoma, sarcomas, traditional radiotherapy, protom beam therapy, hadrontherapy.

INTRODUCTION

Sarcomas are a rare, assorted group of tumours that commonly derive from neoplastic transformation of mesenchymal tissues such as muscle, cancellous bone, cartilage, fat, blood vessels, hematopoietic tissue and nerves [1]. Although about 10.000 soft-tissue sarcomas and 2600 bone sarcomas are diagnosed each year in the US, only a small percentage of these malignancies are located in the spine, where they use to involve multiple vertebrae, the paraspinal musculature, and/or epidural space. In these rare spinal location the most commonly involved histological subtypes are represented by osteosarcoma, chondrosarcoma and Ewing sarcoma [2]. Although these osteosarcomas (OSC) are considered the most common primary malignant bone tumour and only 0,85-4% of all these lesions involve actually the spine, mostly the thoracic and lumbar region, its location in the cervical spine is extremely rarer. As far as we concern, only about 50 cases of cervical OSCs are reported in the literature [3]. It is widely accepted by authors that the best treatment of spinal osteosarcoma consists in a multimodality treatment with a key role played by surgery. An en-bloc resection with largely free margins, according to Enneking classification and to Weinsten-Boriani-Biagini classification is broadly recommended as the treatment of choice. This method is the only one which can guarantee the best results in terms of overall survival and tumor-free survival [2,4,5]. Adjuvant and neoadjuvant chemotherapy has

demonstrated an important role in affording the surgical results, even if it is not able to improve long-term outcomes if associated with an incomplete tumor resection [6]. Conventional radiotherapy such as stereotactic or radio-surgery has been advocated as adjuvant treatment mostly when complete surgical resection is not feasible because risk of causing important instability or deformity or without high operative risks for the patient. Hadrontherapy is one of the most recent and innovative techniques of radiotherapy that uses the physical bullet properties (Bragg peak) of protons such as carbon ions to treat lesions as osteosarcomas that are commonly considered resistant to conventional photon radiotherapy [7-11]. This modality can give a much higher dose of radiation to the tumour with much less side effect to normal tissue secondary to the rapid fall of the radiation power. In this paper we illustrate the case of a 59 years old man with a C2-C3 low-grade osteosarcoma successfully treated only by hadrontherapy with carbon ions.

CASE REPORT

We report the case of a 59 years old man who came to our attention referring a history of worsening cervical pain radiated to the occiput, with associated occasional paraesthesia on the upper limbs without a clear radicular distribution. Patient's clinical history showed systemic hypertension, non-differentiated connective tissue disease, chronic epididymitis, but no history of primary neoplasms.

The neurological examination revealed no neurological deficits. A CT scan of the cervical spine

*Address correspondence to this author at the Department of Neurosurgery, Azienda Universitaria Integrata, Strada di Fiume 477, 34100, Trieste, Italy; Tel: +390403994411; E-mail: leonello.tacconi@asuils.sanita.fvg.it

revealed the presence of a posterior lesion in the right C2-C3 interlaminar space with the characteristics of a bone-destroying cancerous mass involving mainly the right lamina and the spinous process of the axis and extending to the paravertebral muscles. Subsequently the patient underwent further radiological investigations performing a cervical MRI and a total body CT scan (Figure 1A and 1B) which showed an osteolytic lesion with disruption of the spinal process and laminae of C2 and as well as part of C3. A PET was performed as well and this exam enhanced the suspect of a primary malignant mesenchymal neoplasm. A biopsy was performed keeping the biopsy trajectory within the margin of the possible field of lesion removal. The histological diagnosis came back consistent with a low-grade central osteosarcoma. The result was extensively discussed with the patient and the necessity of a multi-model treatment options were made clear to the patient. In particular it was stressed the necessity of an-bloc gross total resection of the tumor followed by chemo- and radiotherapy for a long term tumor control. The patient asked for a second opinion and eventually chose for a particular type of radiotherapy treatment and he went to the Italian National Centre for Hadrontherapy (CNAO) in Pavia. The clinical target volume was established, including the potential area of tumor spread as about a 3–5 mm margin around the borders of the tumor. Three-dimensional treatment planning for C-ion RT was supported using specific software programs; then the dose was calculated and conveyed as the relative biological effectiveness-weighted dose (Gy-equivalent).

C-ion RT was performed once daily, 4 days a week, for a total of 64 GyE in 16 fixed fractions over 4 weeks.

After C-ion RT, patient was clinically evaluated at 4 weeks from the end of treatment and then every 3 months thereafter. The radiological follow up with cervical MRI at 6 months from the end of therapy illustrated an impressive improvement of the tumor that appeared greatly decreased in its major diameters and mostly confined to the bone tissue (Figure 2A and 2B). The same radiological follow up at 5 years from the end of therapy showed complete remission of the osteosarcoma (Figure 3A and 3B) and the patient reported a complete settling from cervical pain and arms' paraesthesia.

DISCUSSION

Osteosarcomas are counted as the most common primary malignant bone tumor; nevertheless, only 0,85-4% of all these lesions are actually located in the spine [1,3], involving most frequently the vertebral body of thoracic and lumbar spine, with possible extension into the spinal canal and pedicles. Hence osteosarcomas located in the cervical spine are extremely rare lesions and only few cases have been reported, so far, in the literature [12]. It is known among authors that the main risk factors for both soft-tissue sarcomas and bone sarcomas development involve regional irradiation and genetic conditions such as Li-Fraumeni syndrome or type 1 neurofibromatosis [13].

The broad European incidence rates are 3.1 per million and present two peaks in children and young

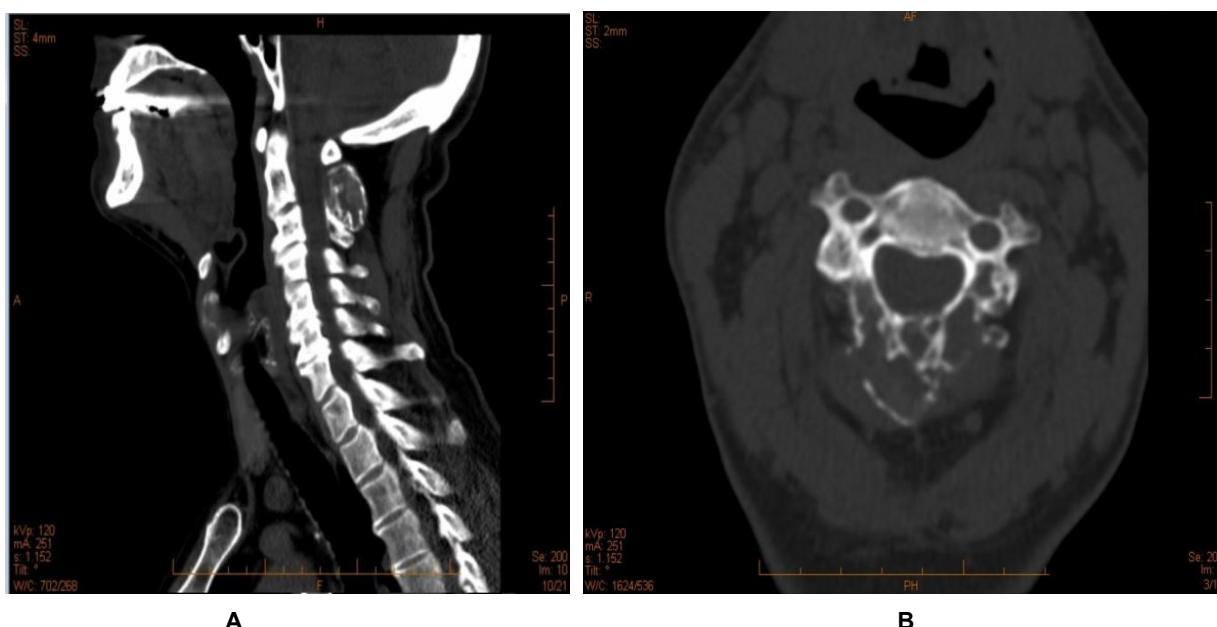


Figure 1:

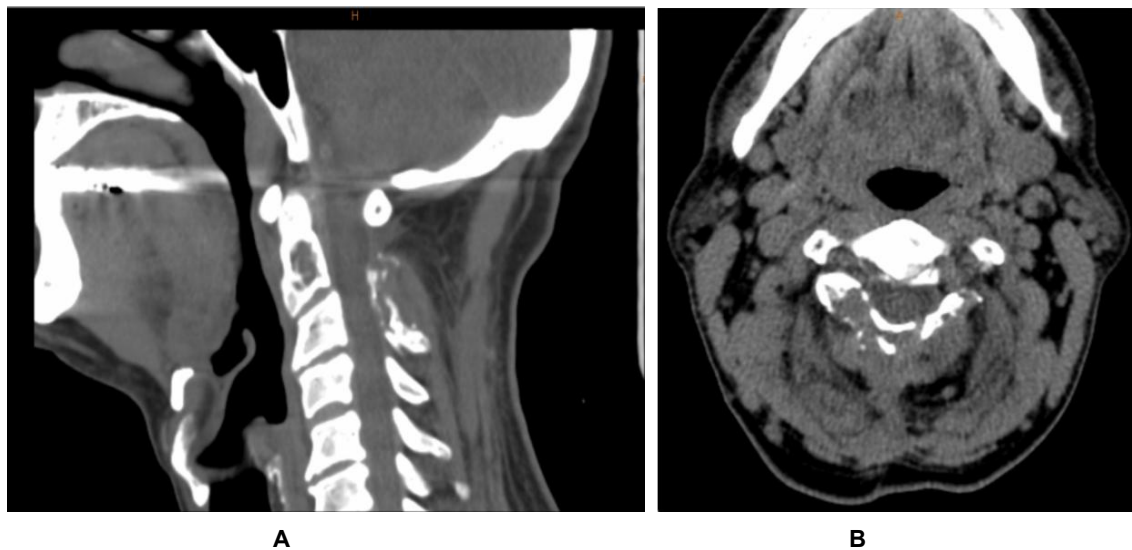


Figure 2:

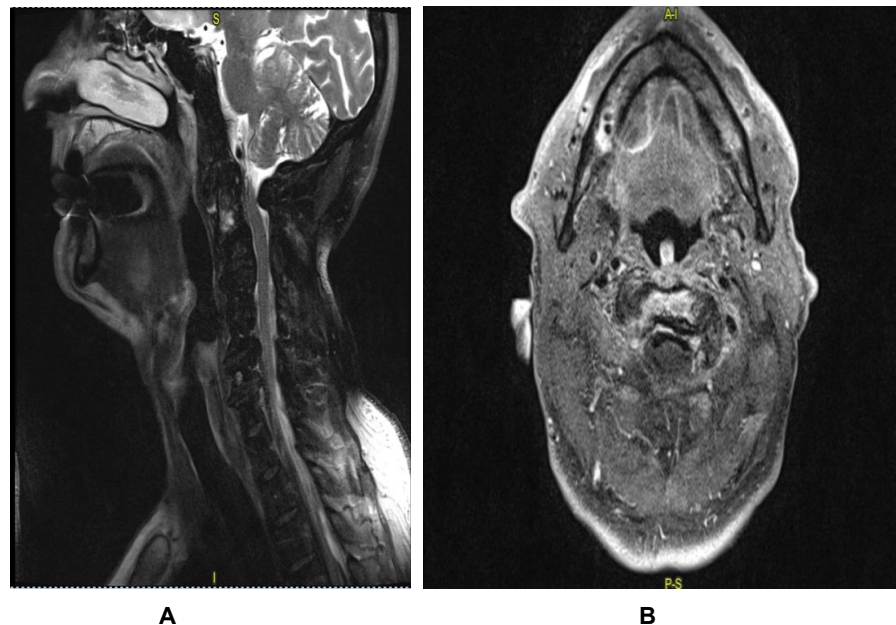


Figure 3:

adults (<24 years) and in the elderly (> 60 years) [7,14]. Even if a wide spectrum of symptoms may occur, the most common symptom, especially in the paediatric population, is pain. It is usually worse at night and not responsive to common analgesic drugs. Although radicular and neurological symptoms are common, they usually arise late in the tumor natural history. Imaging findings in osteosarcoma can vary. Plain X-rays can show a radiolucent-radio dense destructive lesion. Magnetic resonance images can be helpful in narrowing the diagnostic possibilities: the bony part of the tumor is usually hypointense on T1- and T2-weighted imaging, while the contiguous soft tissue bulk is more commonly hyperintense on both T1- and T2-weighted sequences.

The best treatment modality of spinal osteosarcoma is largely accepted to be a multimodality treatment with a key role played by surgery. The treatment goals in these patients is the histological diagnosis with a gross-total resection of the tumour assuring, in the same time, spinal stability, preservation of neurological function and relieve from pain. Surgery is actually the main therapeutic tool for this kind of lesions. Particularly, reviewing data from studies of extraspinal osteosarcoma [15], an advantage in terms of local control and long-term survival has been demonstrated by en-block and wide-margin resections, over tumors treated with intralesional resection. Yet, due to the contiguity of vital structures to the spine, not always the total resection can be accomplished. Because of the

anatomical boundaries of the spine and tumor blood supply, surgical planning is critical. Use of the Weinstein-Boriani-Biagini (WBB) and Enneking spinal tumor classifications can represent a fundamental tool in surgical planning. The WBB classification divides the spine elements affected by tumor into 12 radiating zones and into 5 layers on the transverse plane (A to E, extraosseous soft tissue, intraosseous superficial, intraosseous deep, extraosseous extradural, extraosseous intradural) [16]. The Enneking staging system [17] was actually developed as a surgical classification for primary extraspinal malignancies, but studies by Tomita *et al.* [18] have confirmed its validity in primary spinal tumors. Based on tumor histological findings, anatomical extent and the presence of metastasis, the Enneking system classified malignant tumors as Grade IA (low grade, intracompartmental, no metastasis), Grade IB (low grade, extracompartmental, no metastasis), Grade IIA (high grade, intracompartmental, no metastasis), Grade IIB (high grade, extracompartmental, no metastasis), and Grade III (high grade with metastasis). These classifications are extremely important not only from a surgical point of view but also from a prognostic point of view. Sciubba *et al.* [2] demonstrated that wide-margin en bloc resection of spinal osteosarcomas (Enneking appropriate resection) improves the outcome in terms of tumor-free survival. Nevertheless other authors, such as Rao *et al.* [19] reported no meaning differences in survival or local control rates between en bloc and intralesional resection. Treatment of patients with osteosarcoma of the cervical spine is challenging. The absence of clinical, randomized, prospective trials performed on osteosarcomas of this region has inevitably led to the lack of general consensus about the optimal management. More precisely, the requirement for spinal immobilization and the role of adjuvant therapy are frequent clinical issues. Even if surgery is still considered the main therapeutic modality for cure, many trials indicate the advantage of adjuvant chemotherapy in improving survival of these patients, whereas further trials on the role of neoadjuvant chemotherapy have to be advocated. Chen *et al.* [6] discussed the drugs used for chemotherapy (adjuvant and neoadjuvant) including cisplatin, doxorubicin, methotrexate and ifosfamide, fluorouracil, paclitaxel, perarubicin. Smith *et al.* [20] observed that, for the head and neck osteosarcomas, patients with surgery as the only treatment and patients where the surgical excision was associated to chemotherapy presented similar 5-years survival rate. In addition Chen *et al.* did not find significant differences in the distribution of the risk factors in their chemotherapy and non-

chemotherapy cohorts. Hence, the 5-years mortality rate remains high for patients with osteosarcoma of the spine, with a median overall survival of 29,5 months [14], despite the improvements in surgical techniques and in chemotherapy protocols. This is the main reason for the spreading of interest on the new radiotherapy's technique. OSCs are mostly considered by authors and oncologists as radio-resistant lesions. For their histological characteristics, they seem to have a low response rate to the conventional photon radiotherapy. In addition, it is reported in some studies [2] how previous radiation could be associated with a higher mortality risk, basing on the well-known effect of ionizing radiations in increasing cell tumorigenicity. Thus, even if the use of neutrons in radiotherapy has been considered so far as a standard complementary treatment for patients with sarcomas not suitable for a complete surgical excision, their indications have been restricted due to their high toxicity rate related to their modest ballistic characteristics. On the contrary, protons have recently revealed an interesting efficacy in curing this kind of lesions [7]. A proton's energy is specifically placed in the depth followed by an abrupt decay in dose (Bragg peak effect). Thanks to their physical properties, protons allow a high-precision radiotherapy delivery which can involve the application of very high doses at critical sites with a very low rate of complications. Dosimetric studies confirm that proton therapy drops the whole dose very closed to the target and improves sparing of normal tissue, comparing with photon radiotherapy [11]. As far as we know, the major experience with proton therapy reported in literature concerns uveal melanomas, chordomas, chondrosarcomas and prostate cancer. Thanks to the innovations in controlling the released doses, nowadays also central nervous system tumors, various sarcomas, childhood cancer and head and neck tumors are commonly treated with proton therapy.

The hadrontherapy maybe, one of the most innovative techniques in the oncologists' armamentarium. It is essentially a proton-beam radiotherapy that uses the properties of hadrons as the carbon ions. These protons seem to be capable to release in every single cell they pass through an energy about 24-times higher than the energy released by a common proton. Carbon ions are actually known for their smaller lateral penumbra and the harder dose fall-off after the Bragg peak than proton beams [8-10]. Weber *et al.* [21] reported that the widening of a proton beam is almost 3.5 times larger than that of a carbon beam when compared for the same depth range. Consequentially the carbon ions and the hadrontherapy seem to represent an increasingly important tool to

treat those kinds of tumors generally considered radio-resistant and that grow in critical anatomical zones such as the spinal in very close to important nervous structures. Nevertheless there are very few reports in literature about clinical indications and results of the hadrontherapy, especially in rare tumors like cervical spine osteosarcomas. In this scenario, the case we reported can embody a new perspective in literature about the use of this very innovative technique of radiotherapy.

CONCLUSIONS

Osteosarcomas are rarely localized in the spine, especially in the cervical spine. En-block gross total resection is still considered the best treatment with adjuvant therapy playing an extremely important role. Hadrontherapy with carbon ions might represent one of the most innovative techniques in the armamentarium of the radiotherapists to treat these lesions, known for their resistance to conventional photon therapy. However, we are still at an earlier phase and much larger series will need to determine its really efficacy in the treatment of these tumors.

REFERENCES

- [1] Stiller CA, Trama A, Serraino D, *et al.* Descriptive epidemiology of sarcomas in Europe: Report from the RARECARE project. *Eur J Cancer* 2013; 49(3): 684-695. <https://doi.org/10.1016/j.ejca.2012.09.011>
- [2] Sciubba DM, De la Garza Ramos R, Rory Goodwin C, *et al.* Clinical, surgical, and molecular prognostic factors for survival after spinal sarcoma resection. *Neurosurg Focus* 2016; 41(2): E9.
- [3] Denaro L, Longo UG, Di Martino AC, Maffulli N, Denaro V. Screw migration and oesophageal perforation after surgery for osteosarcoma of the cervical spine. *BMC Musculoskelet Disord* 2017; 18(1): 1-8. <https://doi.org/10.1186/s12891-017-1906-5>
- [4] Bielack SS, Hecker-Nolting S, Blattmann C, Kager L. Advances in the management of osteosarcoma. *F1000Research* 2016; 5(0): 2767. <https://doi.org/10.12688/f1000research.9465.1>
- [5] Bielack SS, Wulff B, Delling G, *et al.* Osteosarcoma of the trunk treated by multimodal therapy: Experience of the cooperative osteosarcoma study group (COSS). *Med Pediatr Oncol* 1995; 24(1): 6-12. <https://doi.org/10.1002/mpo.2950240103>
- [6] Chen YM, Gokavarapu S, Shen QC, *et al.* Chemotherapy in head and neck osteosarcoma: Adjuvant chemotherapy improves overall survival. *Oral Oncol* 2017; 73(September): 124-131.
- [7] Frisch S, Timmermann B. The Evolving Role of Proton Beam Therapy for Sarcomas. *Clin Oncol* 2017; 29(8): 500-506. <https://doi.org/10.1016/j.clon.2017.04.034>
- [8] Matsumoto K, Imai R, Kamada T, *et al.* Impact of carbon ion radiotherapy for primary spinal sarcoma. *Cancer* 2013; 119(19): 3496-3503. <https://doi.org/10.1002/cncr.28177>
- [9] Matsumoto K, Nakamura K, Shioyama Y, *et al.* Treatment planning comparison for carbon ion radiotherapy, proton therapy and intensity-modulated radiotherapy for spinal sarcoma. *Anticancer Res* 2015; 35(7): 4083-4090.
- [10] Pommier P, Sunyach MP, Hu Y, *et al.* [Radiotherapy for sarcoma: hadrontherapy, for whom and what for?]. *Bull Cancer* 2010; 97(6): 657-672.
- [11] Tuan J, Vischioni B, Fossati P, *et al.* Initial clinical experience with scanned proton beams at the Italian National Center for Hadrontherapy (CNAO). *J Radiat Res* 2013; 54(SUPPL.1).
- [12] Chan KY, Sun TF, Kam KM, Shing MK, Poon WS. Cervical spinal osteosarcoma in an adolescent. *J Clin Neurosci* 2012; 19(8): 1172-1174. <https://doi.org/10.1016/j.jocn.2011.09.035>
- [13] Breakey RWF, Crowley TP, Anderson IB, Milner RH, Ragbir M. The surgical management of head and neck sarcoma: The Newcastle experience. *J Plast Reconstr Aesthetic Surg* 2017; 70(1): 78-84. <https://doi.org/10.1016/j.bjps.2016.09.026>
- [14] Ravindra VM, Eli IM, Schmidt MH, Brockmeyer DL. Primary osseous tumors of the pediatric spinal column: Review of Pathology and Surgical Decision Making. *Neurosurg Focus* 2016; 41(August): 1-14.
- [15] Clarke MJ, Price DL, Cloft HJ, *et al.* En bloc resection of a C-1 lateral mass osteosarcoma: Technical Note. *JNS Pediatr* 2016; 18(July): 46-52.
- [16] Boriani S, Weinstein JN, Biagini R. Primary bone tumors of the spine. Terminology and surgical staging. *Spine (Phila Pa 1976)* 1997; 22(9): 1036-1044. <https://doi.org/10.1097/00007632-199705010-00020>
- [17] Enneking WF, Spanier SS, Goodman MA. The Classic: A System for the Surgical Staging of Musculoskeletal Sarcoma. *Clin Orthop Relat Res* 2003; 415(415): 4-18. <https://doi.org/10.1097/01.blo.0000093891.12372.0f>
- [18] Tomita K, Kawahara N, Kobayashi T. Surgical Strategy for Spinal Metastases. *Spine (Phila Pa 1976)* 2001; 26(3): 298-306. <https://doi.org/10.1097/00007632-200102010-00016>
- [19] Rao G, Suki D, Chakrabarti I, *et al.* Surgical management of primary and metastatic sarcoma of the mobile spine. *J Neurosurg Spine* 2008; 9(2): 120-128. <https://doi.org/10.3171/SPI/2008/9/8/120>
- [20] Smith RB, Apostolakis LW, Karnell LH, *et al.* National Cancer Data Base report on osteosarcoma of the head and neck. *Cancer* 2003; 98(8): 1670-1680. <https://doi.org/10.1002/cncr.11716>
- [21] Weber U KG. Comparison of Carbon Ions Versus Protons : The Cancer Journal. *Cancer J* 2009; Jul-Aug; (15): 325-332. <https://doi.org/10.1097/PP0.0b013e3181b01935>

Received on 24-04-2018

Accepted on 15-05-2018

Published on 25-06-2018

DOI: <http://dx.doi.org/10.6000/1929-2279.2018.07.03.5>

© 2018 Morgan *et al.*; Licensee Lifescience Global.

This is an open access article licensed under the terms of the Creative Commons Attribution Non-Commercial License (<http://creativecommons.org/licenses/by-nc/3.0/>) which permits unrestricted, non-commercial use, distribution and reproduction in any medium, provided the work is properly cited.