

Biological and Pathological Study of Prostate Cancer at Localized Stage in Western Algeria

Abdelkrim Berroukche^{1,2,*}, Malika Bendahmane-Salmi^{1,3} and Badreddine Abdelkrim Kandouci¹

¹Research Laboratory of Environment and Health (RLEH), Faculty of Medicine, University Hospital of Sidi-Bel-Abbes, Algeria

²Department of Biology, Faculty of Sciences and Technology, Moulay Tahar University of Saida, Algeria

³Department of Biology, Faculty of Sciences, Djillali Liabes University of Sidi-Bel-Abbes, Algeria

Abstract: *Objective:* To show the contribution of the pathological examination, associated with prostatic specific antigen (PSA), in the early detection of prostate cancer in Western Algeria.

Methodology: This study focused on 160 cases, old between 50-80 years, with histologically confirmed prostate adenocarcinoma and carried out in urology hospitals in western Algeria during the period from 2007 to 2011. Tumor stage, PSA, Gleason score and the degree of tumor differentiation were analyzed.

Results: 135 patients, with a poor prognosis and a Gleason score > 8 index of incurable malignant aggression, have not been the subject of this study. But the other 35 patients were candidates because they had a favorable prognosis with a localized stage that could be curable. Gleason score was between 5-6 in 5 patients with TPSA ≤ 10 ng / ml at differential stage, score of 7 in 10 patients with TPSA between 10-20 ng / ml at moderately differentiated stage and finally a score of 8 in 20 patients with TPSA between 20,1-50 ng / ml at a poorly differentiated stage.

Conclusion: There is a strong correlation between TPSA, Gleason score and the degree of tumor differentiation. Biological and pathological prognosis, established early, can reduce tumor progression.

Keywords: PSA, prostate cancer, urology, Gleason score, tumor progression.

INTRODUCTION

Prostate cancer (Pca) is the most common cancer in men older than 50 years and the second cause of death by cancer after lung cancer in rich countries. Incidence of Pca has been quadrupled in less than 25 years and the mortality rate has increased by 40 % in western world [1]. In Algeria, the prevalence of Pca is unknown and its screening is always late in approximately 80% of metastatic cases [2]. In this country, it was recorded more than 500 new cases of Pca per year [3]. The problem of Pca screening, in Algeria, is the late diagnosis of this cancer which is already at an advanced stage and that the chances of recovery are low. There is a lack of coordination between clinical tests, biological and pathological examinations, so it is an incomplete screening which allows a delayed diagnosis and difficult to slow tumor growth. Prostate cancer is an adenocarcinoma in 95% of cases and it is often most developed in the peripheral zone of prostate gland [4]. Pca progression is usually slow to surrounding tissues. The evolution and prognosis of Pca are related to tumor volume, prostate specific antigen (PSA), tumor stage and the

degree of histological differentiation grade called Gleason score [5]. The objective of this study is to show the contribution of pathological screening of Pca at a localized stage, associated to PSA, in order to eliminate the metastatic risk in patients which dealing in Algerian hospitals.

METHODOLOGY

Population Study

In the early stages of the study, a population was composed of 374 men with urological disorders. Only 204 cases of Pca, aged between 50 and 80 years, were detected and followed during four years from 2007 to 2011. During this study, 54 patients with Pca declined participation. Ultimately, the population consisted of 160 cases of Pca histologically confirmed. In this population, there are 98 cases from urological department in Saida hospital and 62 from urological department of Sidi-Bel-Abbes university hospital, areas located in western Algeria. The distribution of patients by stage of localization of Pca was as follows; 22% for localized stage, 74% for loco regional stage and 4% for advanced stage of Pca. There is no case with subclinical or latent Pca. The criteria for inclusion of Pca cases, in this study, were defined according to the following design parameters: enrolled patients are older

*Address correspondence to this author at the N° 17 cité des frères Moulay, Saida 20000, Algeria; Tel: 0021348518557 (H); Mobile: 00213798520868; E-mail: kerroum1967@yahoo.fr

than 50 years, patients with histologically confirmed Pca, the serum-PSA assay was carried out by the same technique and all patients living in areas of Sidi-Bel-Abbes and Saida for at least ten years and able to be interviewed.

Patients

This study included 160 patients who underwent histological examination of surgical specimens prostatectomy and biopsies between January 2007 and March 2011 at the University Hospital of Sidi-Bel-Abbes. Among these patients, 78 % had a poor prognosis and showed undifferentiated adenocarcinoma, while other patients (22%) have a more or less favorable prognosis because of their localized stage adenocarcinoma. These 35 patients whose chances of curability are intact but exposed to tumor aggressiveness have been an analysis of the relationship between the stage of the cancer, the Gleason score and serum concentration of total PSA (TPSA).

Techniques

TPSA Serum-Assay

All patients were evaluated by determination of the serum TPSA level. Blood samples were collected at the urology department of each hospital and taken directly to the laboratory of biological analysis in the same hospital. Approximately 10 ml of blood were collected intravenously in a dry tube. The blood was centrifuged and serum was frozen at -20 ° C until to be used in the assay. The sera were frozen for a period not exceeding three months and then thawed for achieving TPSA assay knowing that for short periods of freezing and TPSA assay is little changed. TPSA assays are undergone in mini VIDAS analyzer (Bio-Merieux, France). The used method was the technique of enzyme-linked fluorescent assay (ELFA): it is an enzyme immunoassay ELISA "sandwich" in heterogeneous phase where the molecules of PSA are caught between two monoclonal antibodies of murine nature. Reading results of the TPSA assay is done in two stages to a final detection by fluorimetry. The cut-off of TPSA is 4 ng / ml, prescribed by the kit supplier. The detection limit of this method is 0.07 ng / ml and the range of the VIDAS-TPSA kit extends to 100 ng / ml. Samples, with concentrations of TPSA over 100 ng / ml, were retested after dilution in sample diluent TPSA (calf serum + sodium azide 0,9 g/l).

Histology

The samples consisted of prostate biopsies and surgical specimens of prostatectomy, fixed in 10 % formalin and came from the urology department of each hospital, were sent to the pathology department of the University Hospital of Sidi-Bel-Abbes where taking place the macroscopic and microscopic histological examinations. These samples were processed according to the conventional histological techniques. Surgical specimens, fixed in formalin, were cut into thin slices about 3 mm. The paraffin embedding technique was the method of treatment of these fragments. The slides are stained with hematoxylin and eosin and observed under optical microscope from a low to high magnification.

Statistical Analysis

The data and results were processed using Excel software Microsoft Office 2007 on Windows 7. Descriptive analyzes were based on conventional parameters such as numbers, frequencies and percentages for quantitative parameters.

RESULTS

Histological examination shall specify the histological type, grade, Gleason score and capsular crossing. All 160 incident cases of Pca, in our study, have been a distribution depending on the stage of cancer as follows: 22 % had a localized stage, 74 % with locally advanced stage and 4% with metastatic stage. Among the 160 patients Pca, only 35 patients (22%) were the subject of our concern. These patients have a Pca at a localized stage and run the metastatic risk. These patients were monitored for the study of the relationship between stage of Pca, Gleason score and TPSA-serum concentration. These patients were divided according to the risk of invasion or tumor aggressiveness: 5 patients with localized stage at low risk (LSLR), 10 patients with localized stage at intermediate risk (LSIR) and 20 patients with localized stage at high risk (LSHR) (Figure 1).Whereas other Pca patients (78%) were not the subject of this study due to pathological examination, which revealed a poor prognosis with high Gleason score and high grade of malignancy that corresponding to a metastatic stage with score more than 8.

This present study shows that serum-TPSA concentration increases with the rise of Gleason score, evolution of tumor stage and degree of differentiation of Pca (Table 1). At serum-TPSA between 20 and 50

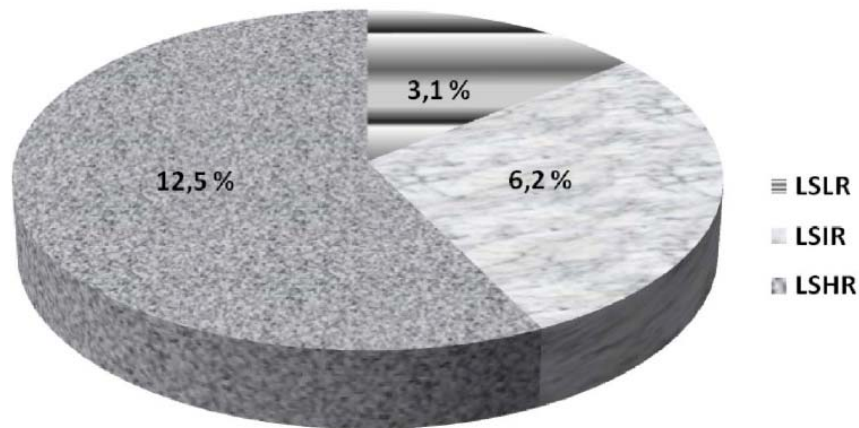


Figure 1: Distribution of Pca patients according tumor aggressiveness risk.

LSLR: localized stage at low risk.

LSIR: localized stage at intermediate risk.

LSHR: localized stage at high risk.

ng / ml, there was a risk of tumor invasion. There were 20 Pca patients who were at high risk of tumor invasion at the capsular margin of the prostate gland and with high probability it will exceed the outer margins of the prostatic capsule (Table 1). Gleason score 8 represents a very high risk in patients with localized Pca. This score favors the invasive progression of Pca to other tissue adjacent to the prostate gland. Prostate tumors, with Gleason scores between 5 and 6, are considered tumors located just at the periphery of the prostate gland in contrast to tumors with Gleason score less than 5, which are confined to the gland or located in the center of gland (Table 1). Prostate tumors, with Gleason score between 2 and 4, represent cancers of low grade malignancy and are considered adenocarcinomas sitting in the center of the prostate gland (Table 1). These tumors are at slow evolution which can be spread over a decade. Unlike tumors, with score between 5 and 8, which considered more aggressive cancers. Prostate tumor, with Gleason score of 4 or 5, is considered a cancer which differentiated cell and tissue architecture closely like a benign prostatic hyperplasia (BPH) or a prostate gland normal (Table 1). This type of differentiation was observed in 3,1 % of our Pca patients with a Gleason

score of 5 and not observed in other patients with a score greater than 5. In addition, moderately differentiated and poorly differentiated stages of Pca predominated in 30 patients (Table 1).

Among the 35 Pca patients, with Gleason scores between 5 and 8, there were 5 patients with differentiated prostatic adenocarcinoma. The architecture of the prostate tissue was more or less similar to that of a normal or hypertrophic prostate. This type of adenocarcinoma was composed of individualized glands. The epithelium of acini was cylindrical, single layered, and composed of cells with large oval basal nucleus, with a dark and granular eosinophilic cytoplasm. The activity of nuclei was intense with a vesicular chromatin and condensation in some periphery of the nuclear membrane that may evoke small nucleoli. The contours of the nuclei were regular with uniform size. The basal cell layer lining the acini, after staining with the haematoxylin-eosin (HE), was neatly continuous (Figure 2).

In group of patients with moderately undifferentiated Pca, the acini are often irregular, consisted of a single layer of cells which nucleus had increased volume that

Table 1: Types of Prostate Adenocarcinoma at Localized Stage According to Biological and Pathological Prognosis

Tumoral stage of Pca	Number of patients	TPSA (ng / ml)	Gleason Score	Degree of differentiation
LSLR	5	≤ 10	5 – 6	differentiated
LSIR	10	10 – 20	7	moderately differentiated
LSHR	20	20,1 – 50	8	Poorly differentiated

LSLR: localized stage at low risk.

LSIR: localized stage at intermediate risk.

LSHR: localized stage at high risk.

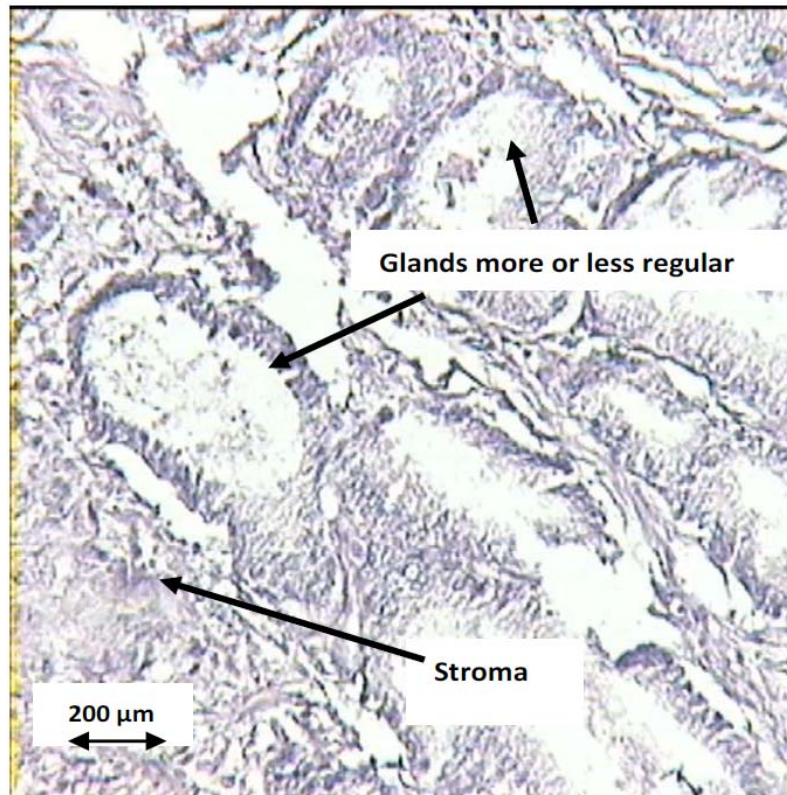


Figure 2: Differentiated prostatic adenocarcinoma (Observed at light microscope with magnification $\times 400$).

contains one or more nucleoli. On the other hand, the basal cell layer was disappeared (Figure 3).

The histopathological description of poorly differentiated adenocarcinoma shows prostatic parenchyma that was the seat of malignant neoplastic cell proliferation with a nature of infiltrative carcinoma

arranged in glands with variable size and shape, sometimes backed back to back or spaced from each other or sometimes having a merged appearance. This cellular architecture was associated with a marked cytonuclear atypia, frequent abnormal mitoses and many prominent basophil nucleoli (Figure 4).

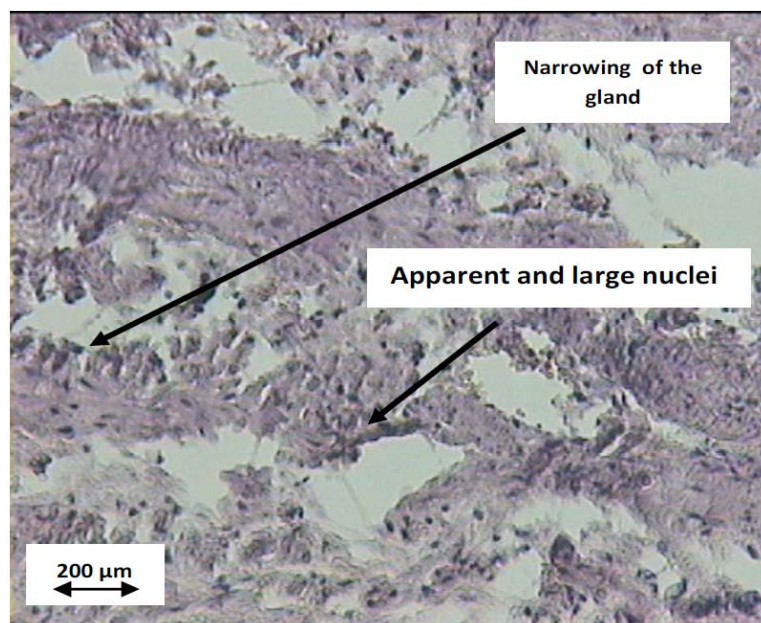


Figure 3: Moderately Differentiated prostatic adenocarcinoma (Observed at light microscope with magnification $\times 400$).

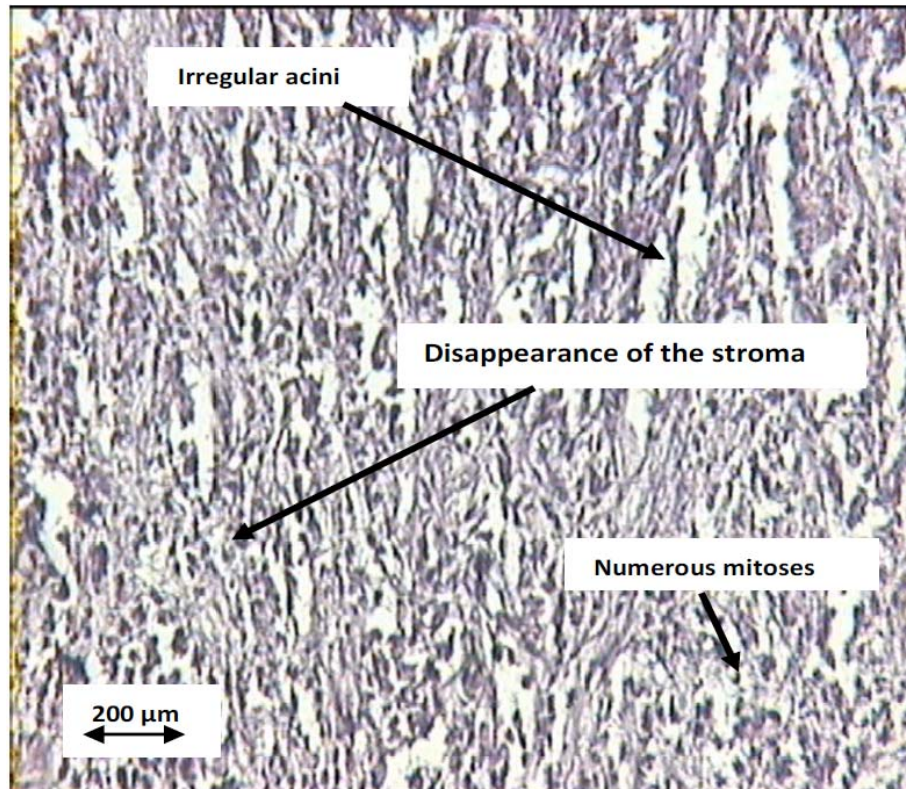


Figure 4: Poorly differentiated prostatic adenocarcinoma (Observed at light microscope with magnification $\times 400$).

DISCUSSION

The histological grade of prostate biopsy, used alone or in combination with the other preoperative parameters (clinical stage and PSA), is recognized as one of the predictors of histological pathological stage of Pca [5]. Therapeutic decision is based on prognostic factors and requires knowledge of the natural history of Pca, as well as information on the age of the patient, clinical data, serum-PSA assay, the results of biopsies including Gleason score [6]. Among predictive factors of pathological stage, histological grade is recognized as one of the most important [7, 8]. Biological evolution of prostatic adenocarcinoma with a Gleason score located at the two extremes is predictable. Patients diagnosed with a Gleason score between 2 and 4 are usually patients who have a very good prognosis. For those with Gleason score between 8 and 10, their prognosis is unfavorable [7, 9, 10]. The prognosis of Pca with a Gleason score between 5 and 7 is less predictable [6]. However, some studies suggest that tumors with a Gleason score between 5 and 6 behave in the same way as those with a lower score and have a better prognosis than those with a score of 7 [7, 10, 11]. The same authors suggest that Pca with Gleason score 7 is undifferentiated and assimilate it to those of score with 8 or more. In the recent series of radical

prostatectomies, Gleason score 7 is found in 20 to 50 % of surgical specimens studied [10, 12-14]. In our study, 125 Pca patients had poor prognosis with a Gleason score between 8 and 10 and their cancer had a rapid healing and low chances of curability. For this reason, these patients could not be present in the group of 35 patients developing localized adenocarcinoma, which were selected to study the relationship between the stage of Pca, Gleason score and serum TPSA values. Whereas the other 35 Pca, which were analyzed in this study, have a Gleason score between 5 and 8. These patients were exposed to various risks of tumor aggressiveness and a possibility to develop different levels of tumor malignancy, their histological prognostic was between a good and a poor prognosis. Our attention focused on this group of patients to follow evolution of their cancer.

Histological grade, used alone or in combination with other preoperative parameters (clinical stage and PSA), is recognized as one of the predictive factors of pathologic stage without biological or clinical progression of Pca [5].

The Gleason score 7 was considered a witness undifferentiated tumor. For some authors, it is a single entity and well differentiated from other categories 2-6

and 8-10 [10, 11]. Biological recurrence rates are higher than those tumors with a score between 2 and 4 and lower than those tumors with a score between 8 and 10, following a curative treatment (radiotherapy or radical prostatectomy) [7, 10, 11].

In the literature, the rates of extra-prostatic stage, seminal vesicle invasion and lymph node metastasis were higher for tumors with a Gleason score greater than 8 for those with a score of 7. Similarly, tumors with a score of 7 had a small volume and aneuploidy rate is lower compared to tumors with a score of 8 or more [15, 16].

In our study, rates of extra-prostatic extension or metastasis were not higher for tumors with a score between 8 and 10 which are represented by only 4 % of Pca patients. The only explanation could be the result of the small number of patients in this study.

In our series, represented by 35 prostatic adenocarcinomas, it was not found a high grade prostatic intra epithelial neoplasia (PIN). These precancerous lesions, when present, usually show an early onset of tumor invasion. The diagnosis of these lesions is not always easy, especially on biopsies with 1 mm wide and 15 mm long [17]. Precancerous lesions should be differentiated from benign proliferative lesions and seminal vesicle epithelium. Nevertheless, the presence of nuclear atypia and interruption of the basal cell layer are decisive diagnostic criteria. In an autopsy study, precancerous lesions are observed respectively in 46 % and 72 % of men old between 60 and 70 years [18]. It is possible that in our study we did not observe high-grade precancerous lesions (or PIN) not due to diagnostic difficulties but because of the absence of these lesions. Finally, this study seeks to install a better strategy combining all diagnostic tests and bring the patient to be a well and to avoid him the stress of metastatic risk.

CONCLUSION

High PSA values, associated with an alarming clinical diagnosis, allow to encourage early pathological examinations to establish a final and decisive diagnosis of Pca at a localized stage. The majority of patients, in our study, had a poor prognosis with advanced stage and Gleason score between 8 and 10, which require intense therapeutic monitoring although the chances of curability are low. Whereas Pca patients, which were the subject of our work, had a favorable prognosis with localized stage. There is a strong correlation between a high PSA and Gleason score or degree of

differentiation, which helps to install an advanced therapeutic strategy to prevent irreversible damage caused by the progression of Pca.

ACKNOWLEDGEMENT

The authors thank all members of pathology laboratory of Sidi-Bel-Abbes university hospital and doctors of Urology Department in Saida Hospital, for their great contribution during interviews with patients, as the medical staff who helped in identifying and contacting patients and finally all men who agreed to participate in this study.

CONFLICT OF INTEREST STATEMENT

The authors declare that they do not have any conflict of interest.

REFERENCES

- [1] Grosclaude P. Evolution de l'incidence et de la mortalité par cancer en France de 1978 à 2000. *Prostate* 2003; *Invs.sante.fr*.
- [2] Berroukche A, Bendahmane M, Kandouci BA. Performance du dosage de PSA dans le dépistage précoce du cancer de la prostate. *Etude cas-témoins dans un hôpital de l'Ouest Algérien. Immuno-analyse et biologie spécialisée* 2012; 27: 54-60.
<http://dx.doi.org/10.1016/j.immbio.2012.01.010>
- [3] Ferlay J, Shin HR, Bray F, Forman D, Mathers C, Parkin DM. GLOBOCAN 2008 v1.2, Cancer Incidence and Mortality Worldwide: IARC Cancer Base No. 10, <http://globocan.iarc.fr>.
- [4] Shannon BA, McNeal JE, Cohen RJ. Transition zone carcinoma of the prostate gland: a common indolent tumour type that occasionally manifests aggressive behaviour. *Pathology* 2003; 35(6): 467-71.
<http://dx.doi.org/10.1080/00313020310001619154>
- [5] Castanho MJ, Barros LC. Prognostico de Cancer de Prostata: Probabilidade e Possibilidade. *Mat Apl Comput* 2007; 8(3): 371-79.
- [6] Rigaud J, Tiguert R, Fradet Y, Bouchot O. Salvage radical prostatectomy after radiotherapy failure in localized prostatic cancer. *Prog Urol* 2002; 12(6): 1179-87.
- [7] Tiguert R, Ravery V, Grignon DJ, Sakr W, Wood DP, Edson Pontes J. Le grade principal du score 7 de Gleason de la pièce opératoire corrélé à la progression biologique des patients traités par prostatectomie totale. *Prog Urol* 2002; 12: 31-36.
- [8] Stamey TA, Yemoto CM, McNeal JE, Sigal BM, Johnstone IM. Prostate cancer is highly predictable: a prognostic equation based on all morphological variables in radical prostatectomy specimens. *J Urol* 2000; 163(4): 1155-60.
[http://dx.doi.org/10.1016/S0022-5347\(05\)67713-0](http://dx.doi.org/10.1016/S0022-5347(05)67713-0)
- [9] Mariano MB, Tefilli MV, Fonseca GN, Goldraich IH. Laparoscopic radical prostatectomy: 10 years experience. *Int Braz J Urol* 2009; 35(5): 565-71.
<http://dx.doi.org/10.1590/S1677-55382009000500008>
- [10] Tefilli MV, Gheiler EL, Tiguert R, *et al.* Role of radical prostatectomy in patients with prostate cancer of high Gleason score. *Prostate* 1999; 39: 60-66.
[http://dx.doi.org/10.1002/\(SICI\)1097-0045\(19990401\)39:1<60::AID-PROS10>3.0.CO;2-U](http://dx.doi.org/10.1002/(SICI)1097-0045(19990401)39:1<60::AID-PROS10>3.0.CO;2-U)

- [11] Fendler JPH, Dujardin T, Bringeon G, Adeleine P, Devonec M, Perrin P. Progression après prostatectomie radicale pour cancer de la prostate: critères pronostiques et place du PSA dans la surveillance. *Prog Urol* 1992; 2: 58-65.
- [12] Blute M, Lau W, Sebo T, Zincke H. Prognostic factors for survival in patients with pathological Gleason 7 prostate. Is there a difference in outcome between Gleason 3+4 versus 4+3. *J Urol* 2000; 163: 320.
- [13] Chan TY, Partin AW, Walsh PC, Epstein JI. Prognostic significance of Gleason 4+3 tumor at radical prostatectomy. *J Urol* 2000; 163: 320.
- [14] Ukimura O, Coleman JA, de la Taille, *et al.* Contemporary role of systematic prostate biopsies: indications, techniques, and implications for patient care. *Eur Urol* 2013; 63 (2): 214-30.
<http://dx.doi.org/10.1016/j.eururo.2012.09.033>
- [15] Ravery V, Toublanc M, Hermieu JF, Boccon-Gibod L. Specimen gleason score 7 with predominant grade 4 adversely impact on outcome after radical prostatectomy. *Eur Urol* 2000; 37: 394.
- [16] Sakr WA, Tefilli MV, Grignon DJ Jr., *et al.* Gleason 7 score prostate cancer: A heterogeneous entity? Correlation with pathologic parameters and disease free survival. *J Urol* 2000; 161: 243.
- [17] Varma M, Berney DM, Algaba F, *et al.* Prostate needle biopsy processing: a survey of laboratory practice across Europe. *J Clin Pathol* 2013; 66(2): 120-3.
<http://dx.doi.org/10.1136/jclinpath-2012-200993>
- [18] Miller GJ, Brawer MK, Sakr WA, Thrasher JB, Townsend R. Prostate cancer: serum and tissue markers. *Rev Urol* 2001; 3(2): 11-9.

Received on 26-03-2013

Accepted on 10-04-2013

Published on 30-04-2013

<http://dx.doi.org/10.6000/1927-7229.2013.02.02.7>